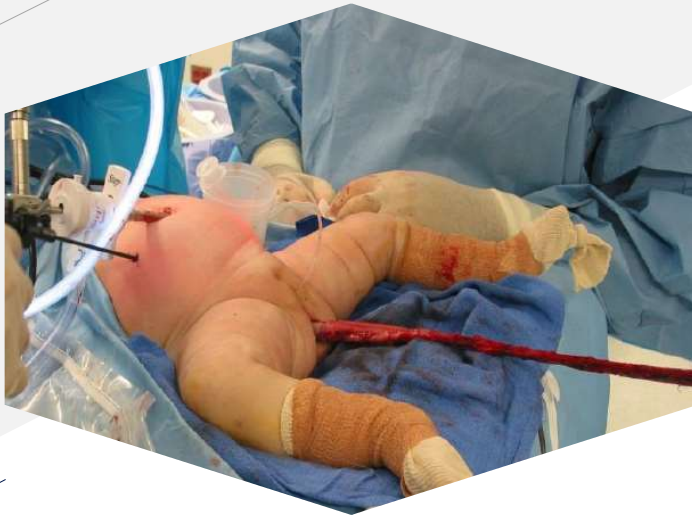



# Hirschsprung Disease:

## Long segment disease

**Samuel Negash, M.D**

Unit of Paediatric Surgery

Addis Ababa University



# OUTLINE

1. Introduction
2. Long segment HD
3. Total colonic HD
4. Near total HD

# 1. Introduction



# Definitions

No formal classification

- **Long-segment HD** - proximal to splenic flexure / mid-transverse
- **Total colonic aganglionosis** - usually also include some distal ileum
- **Near-total intestinal aganglionosis** – most of small bowel is involved  
(have only 10-40 cm jejunum)

# Differences from Classic HD

- **Risk factors** – more likely if Family history, syndromic HD
- **Pathogenesis** – may be acquired
- **Presentation** - may be late (after weaning from breast milk)
- **Clinical evaluation** - Don't do well with irrigation
- **Rectal biopsy** - There might not be hypertrophic nerves or abnormal AchE staining
- **Complication** – Higher rate of soiling, excoriation, enterocolitis, HD associated IBD

## 2. Long segment HD



# Initial surgery: Ileostomy vs Colostomy

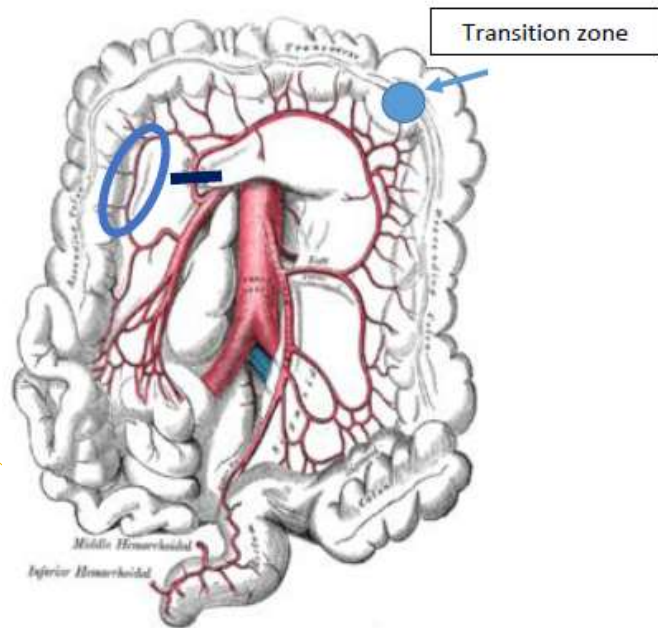
	Leveling Colostomy	Ileostomy
Stoma management	easier	Difficult
Dehydration	Less likely	More likely
Colonic blood supply	Marginal artery Interrupted	Not affected
Remaining colon	All distal colon discarded during pullthrough	Need irrigation every 2-3 wk to make sure distal colon is emptying
Number of procedures	2 (colostomy pullthrough)	2 or 3 (protective ileostomy may be done for long segment requiring derotation)
Pathologic diagnosis	Frozen section (not 100% reliable)	Definitive pathology (100% reliable)

- **Ileostomy preferred in long segment disease** because **frozen section not reliable, marginal vessels not reliable**, and risk of **severe excoriation** postop. \*Left colon HD that need mobilization and taking down middle colic may also require ileostomy if right marginal not present

# Initial surgery: Total Colonic mapping

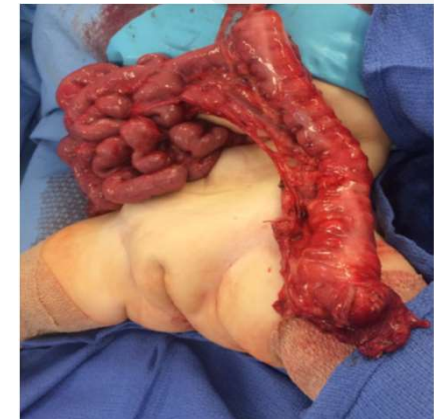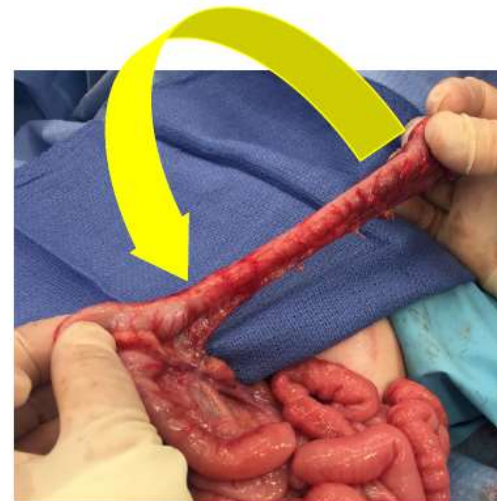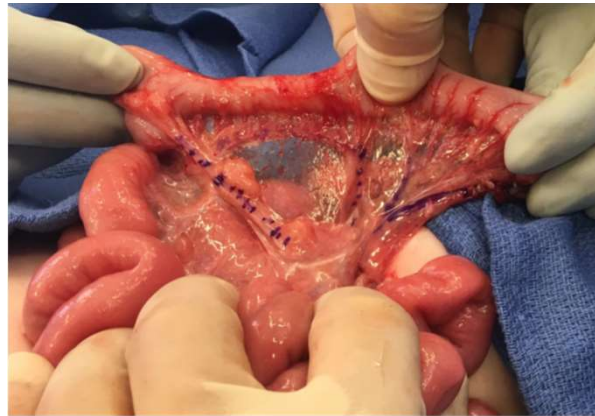
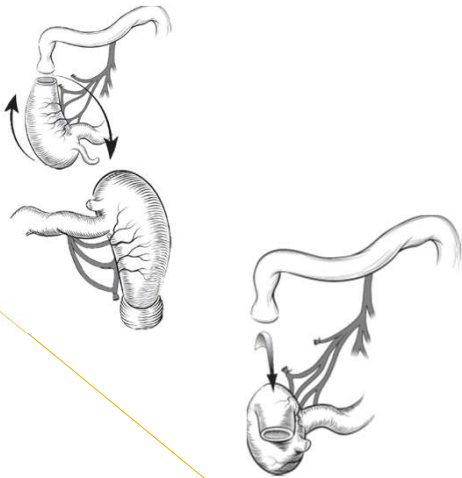
- Don't do colectomy based on frozen section (unreliable above splenic flexure)
- Don't stop taking biopsy when get ganglion cells (skip lesions is ass. with long seg.)
- Biopsies should be full thickness (hypertrophic nerves are in submucosa)
- At least 4 biopsies should be taken to affect management
  - splenic flexure
  - mid transverse
  - hepatic flexure
  - Ascending (around level of right colic artery)

# Pullthrough of right colon



- **Taking down middle colic artery:** Make sure rt marginal is present (absent in 20-40% general population). Right marginal not well developed in newborn (better to postpone pullthrough after 6mo).

# Pullthrough of right colon



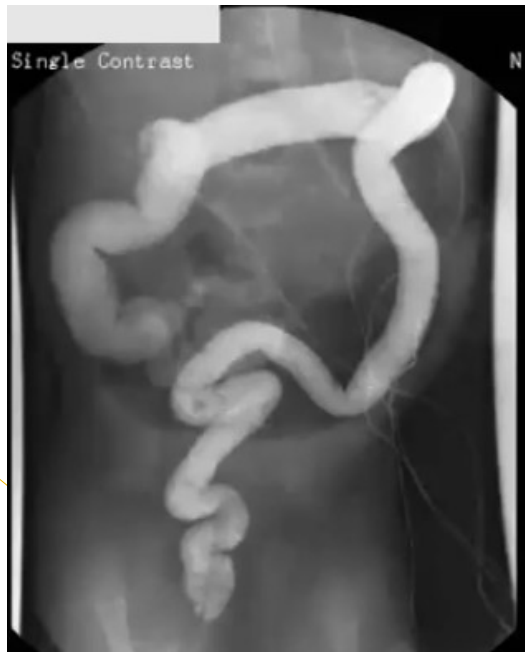- **Deloysers derotation.** After detaching the hepatic flexure the right colon must be de-rotated for the hepatic flexure to reach the anus. Ileostomy must be taken down and duodenum may need kocherization. Be careful not to pullthrough a very short right colon because ileocecal valve in pelvis may cause obstructive symptoms.

**?Weather or not to reopen protective ileostomy?** If protective ileostomy done, careful attention to technique is required to preserve marginal artery (also when closing the stoma).

### **3. Total colonic HD**

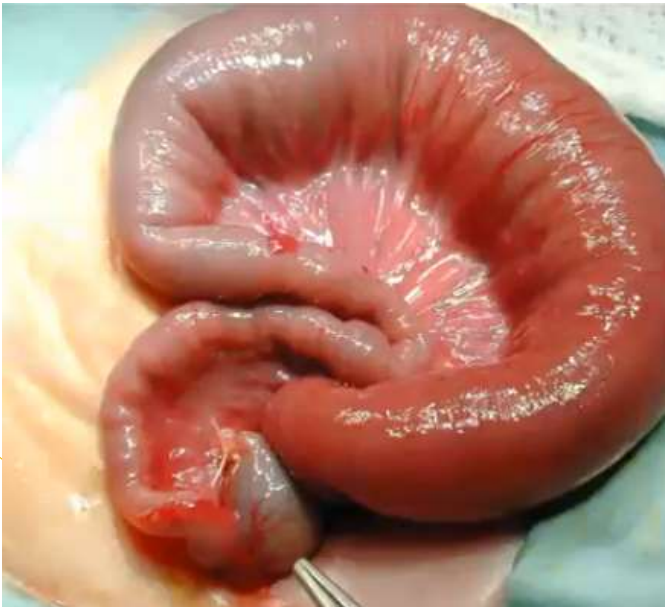

# Imaging



- **contrast enema** shows no transition zone, reflux of contrast into a dilated ileum (and retention of contrast on delayed film) . Classically colon is foreshortened with question mark appearance.

# Initial surgery



- **Intraop finding:** usually only terminal ileum involved. **End ileostomy** will reduce overspill but a **loop ileostomy** can act to vent the downstream segment. **Irrigations of the distal bowel (1-2/week)** may be considered to avoid accumulation of stools in the defunctionalized colon.

# Ileostomy care

- **Observation for dehydration**
- **Sodium supplementation** - started with 1 g/day and increased as needed
  - co-transporters glucose and electrolytes and is thus fundamental (loss leads to FTT)
  - Adequacy of supplementation can be monitored by maintaining a urine sodium > 25 mEq
- **Managing high output** – consistency and thickness depend on diet and peristalsis
  - **Exclude stricture** (obstruction leads to inc peristalsis>>dec absorption)
  - **Dec glucose** (absorb water, will not thicken)
  - **Add Fiber** 0.5g/kg (inc bulk-easily pushed, dec peristalsis) **or Pectin** 4 g/kg (soften+inc bulk)
  - **Loperamide** (dec peristalsis)- use is off label in children (0.08-0.24mg/kg- cant exceed 3mg/d in children<3yr)

# Age for surgery

Authors wait variable amounts of time, ranging from 6 mo to 3 yr.

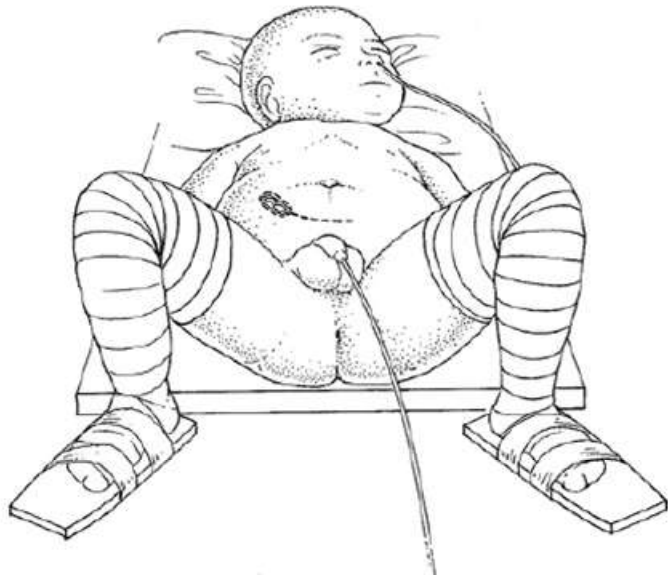
- **8 to 12 months** is a good rule of thumb
  - child is **thriving** (weight gain)
  - ileostomy output **thicken** (<20 mL/kg , apple sauce consistency) so that excoriation is less
  - **marginal vessels** well developed

# Options of pullthrough

no prospective or well-controlled series = ? Do same surgery as for classic HD

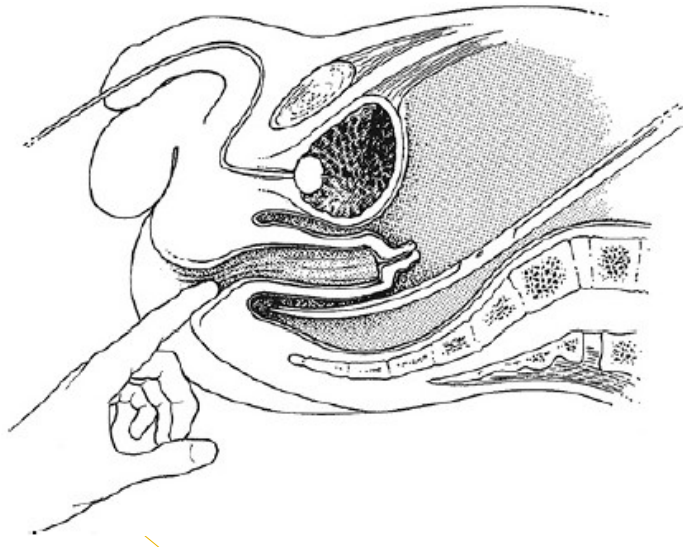
- **Straight ileoanal** – swenson/Soave
- **Ileo-duhamel** = provides reservoir
- Other options
  - **Ileal J Pouch** – leaving a short Duhamel pouch is technically easier and may give same result
  - **Colon patch** = dec stool (inc water absorption) but dilate overtime>> chronic enterocolitis
    - **Ileo kimura** (Rt colon patch)
    - **Ileo Martin** (Lt colon patch)
- **Permanent ileostomy** –down's or other genetic abnormalities, associated ARM, short bowel

# Ileo-Duhamel



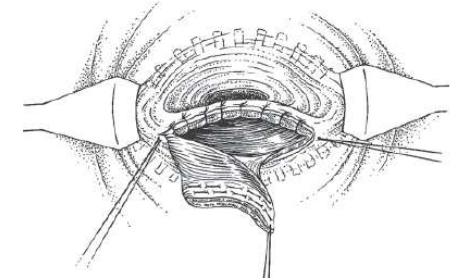
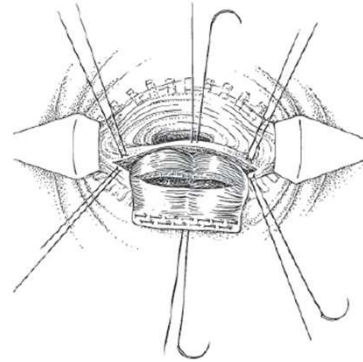
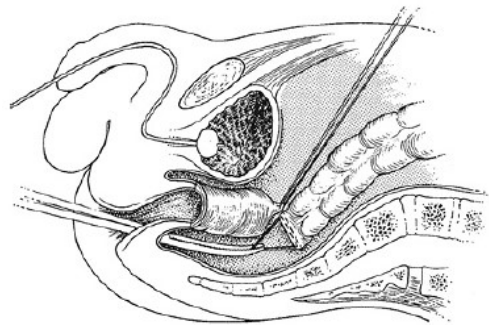
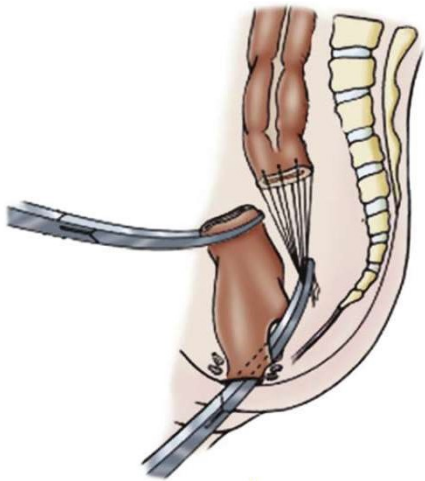
- **Ileostomy mobilization & Colectomy:** lithotomy, take down ileostomy, divide mesentery as needed to allow sufficient length. An additional incision (pfnannenstiel/midline) can be used if the surgeon has difficulty through the ileostomy incision alone. Colectomy is easiest to start proximal and work your way to the distal sigmoid, dividing the mesentery and omentum as you go.

# Ileo-Duhamel



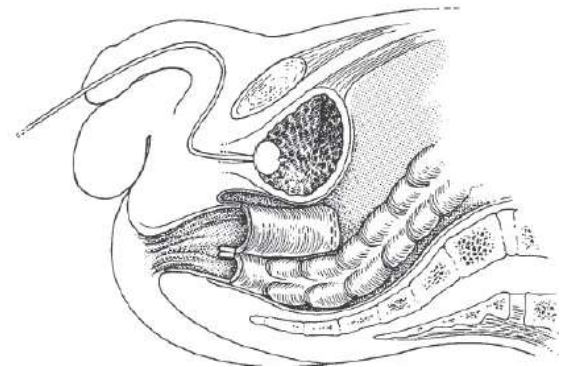
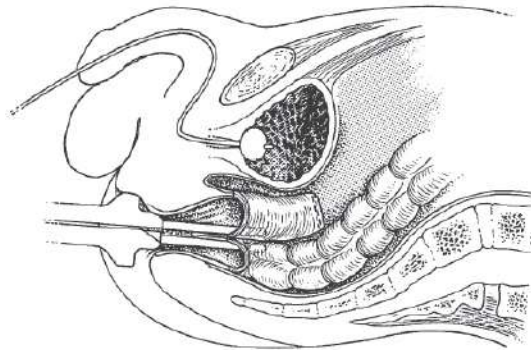
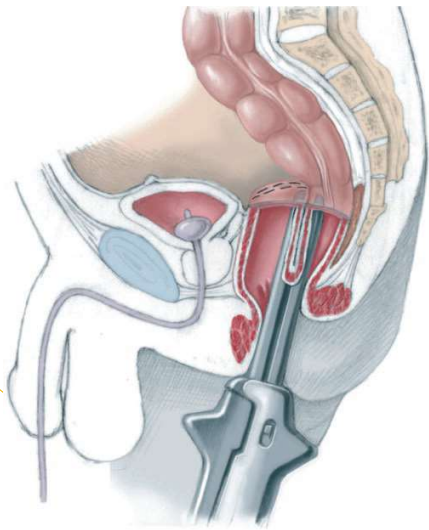
- **Developing retrorectal space:** Hold up on the sigmoid colon to create tension. Identify ureters and divide peritoneum along the rectum down to the peritoneal reflection. Here the two leaves of mesentery diverge and between them is the retrorectal space (fatty layer). Dissect the retrorectal space using blunt dissection with a finger, sweeping 3–9 o'clock around anus. dissection is carried down to the pelvic floor so that an assistant's finger can be felt when inserted no further than 1–1.5 cm into the anus

# Ileo-Duhamel



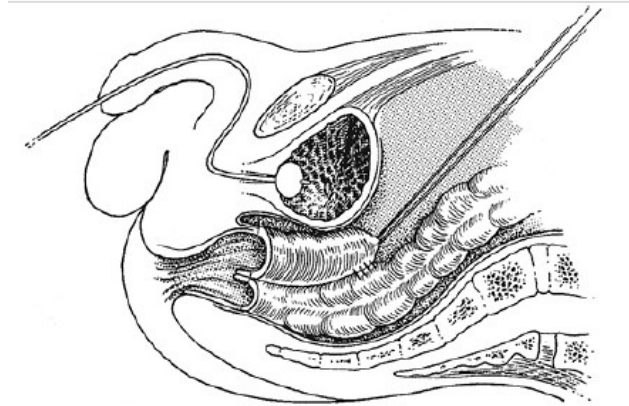
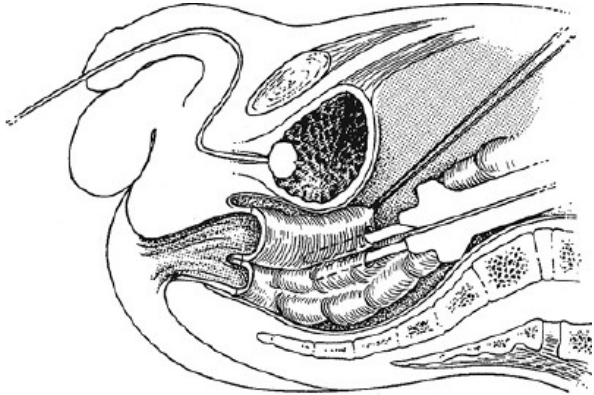
- **Pullthrough and anastomosis:** Place Lonestar retractor with pins at the anocutaneous junction (important b/c Duhamel is prone to constipation). Stay suture on remaining distal bowel to retract it anteriorly. From above, pass a clip with a pledget loaded through retro-rectal space and position in midline to not more than 5 mm above dentate line. Make transverse incision in the posterior rectal wall, cutting directly onto the pledget. Extend circumferentially as a curve for a total length of 1 cm (incision should look like a smile rather than a straight line). Babcock is visualized from the abdomen and antimesenteric corner of the ileum is grasped and pulled through retrorectal incision. Ensure that the pulled-through ileum is not twisted. Complete the anastomosis by placing sutures and initially leaving them untied (“divide and conquer” approach to fill in the gaps). The 6:00 position contains a staple line, therefore sutures placed on either side at the 5:30 and 6:30 position.

# Ileo-Duhamel



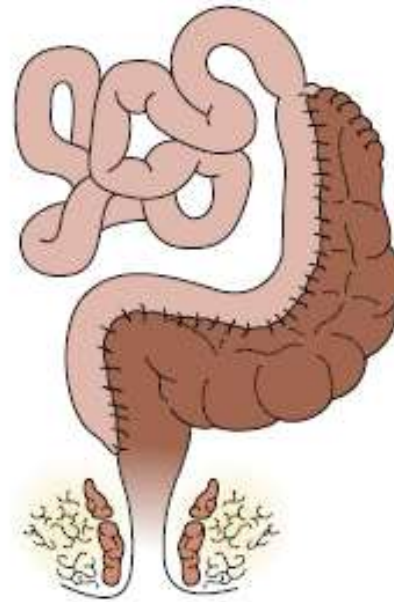
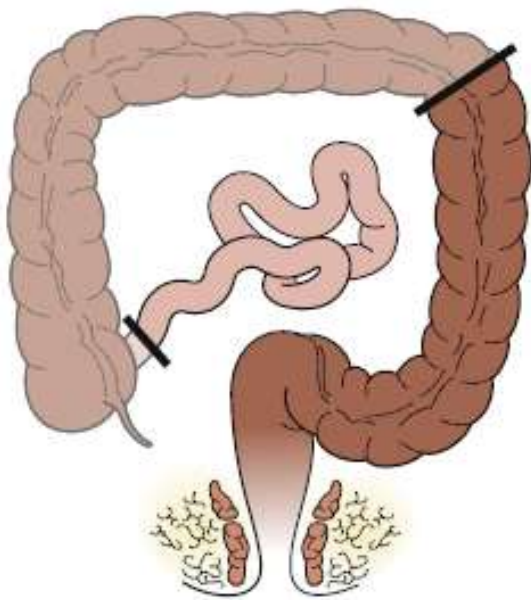
- **Stapling rectal pouch** : Once the anastomosis has been completed, place stapler between the 11:00 and 1:00 sutures with one arm in the native rectum and the other in the pulled-through ileum. There is always a small “spur” because the stapler doesn’t divide all the way to the end of the instrument, but in total colonic disease this is acceptable.

# Ileo-Duhamel



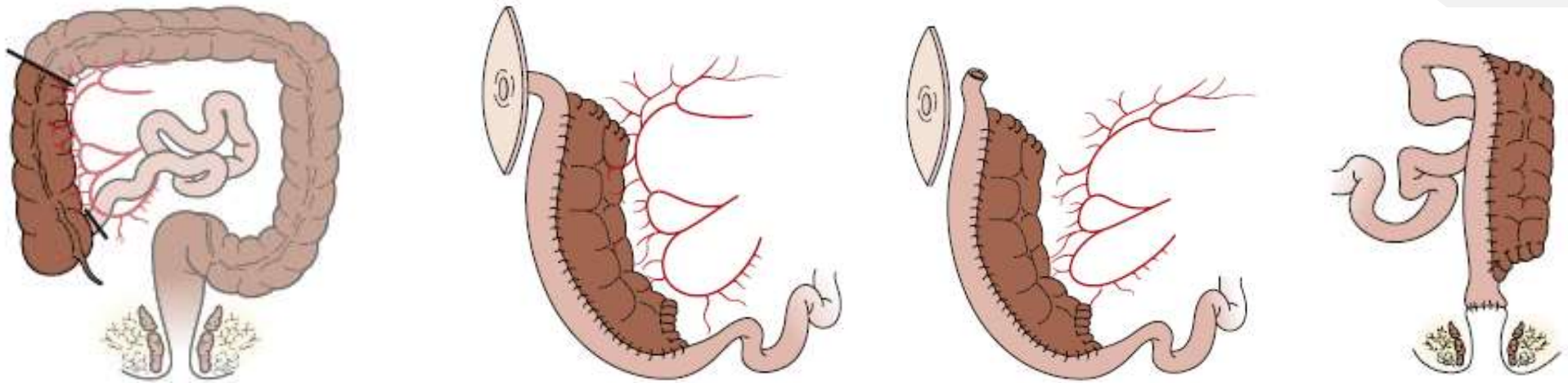
- **Excision of redundant rectum :** To avoid a spur, additional stapling from the abdomen may be done to anastomose the top of the native rectum (stapler inserted via enterotomy of ganglionated bowel and incision is finally sutured to aganglionic rectum). The redundant aganglionic rectum is then resected down to the peritoneal reflection with an automatic stapling device. For 'classic' segment disease, removal of the native rectum from a point just above the staple line will leave a 5–6 cm. For TCA, pouch can safely be left 1–2 cm longer. This means that the native rectum can be removed through the ileostomy incision (deep pelvic dissection may not be needed).

# Ileo-Martin



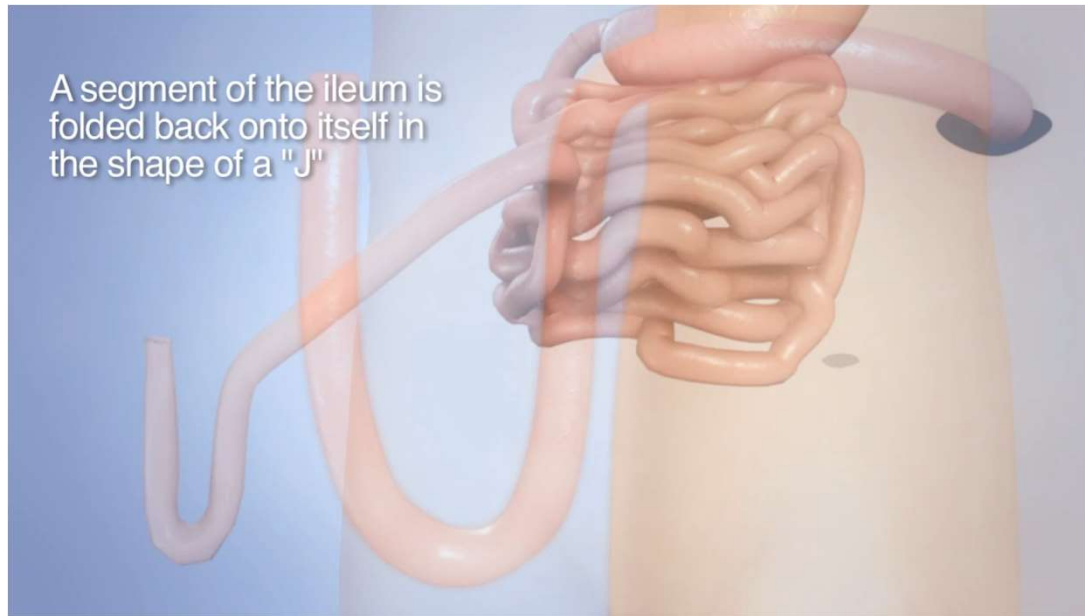- **Martin:** similar to Duhamel, but the whole left colon is left with long anastomosis to ileum. Patients do well short term, but problem with bacterial overgrowth in the long term (diarrhea, severe inflammation and ulceration). Require revisional surgery/stoma.

# Ileo-Kimura



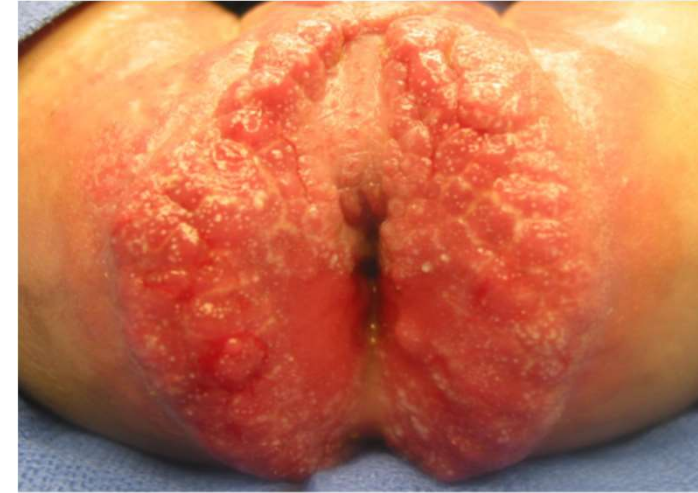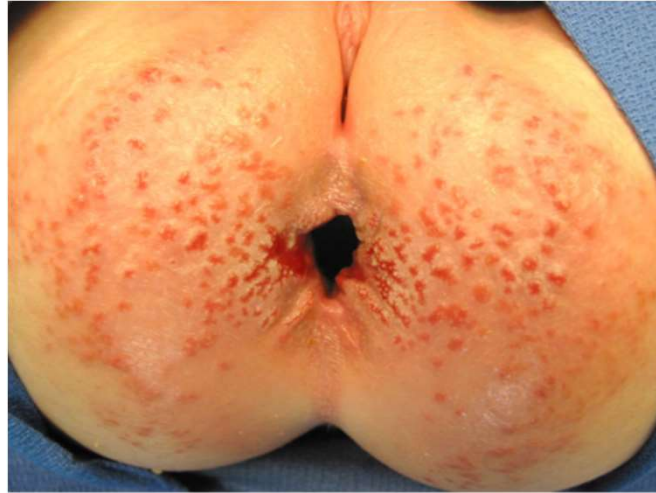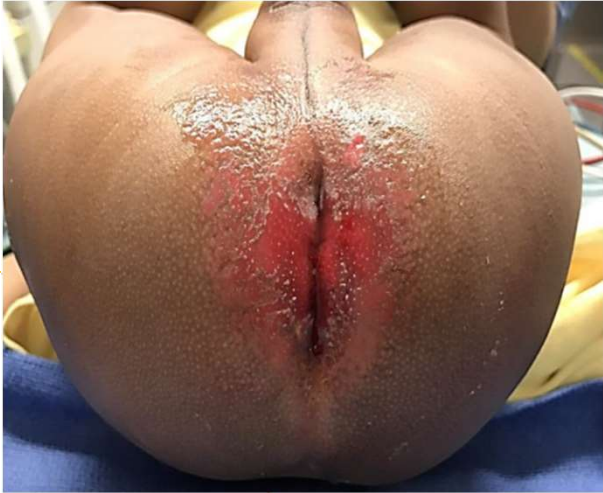- **Kimura:** advocated a staged procedure considering right colon has better absorption of water than left. The ganglionic small bowel is anastomosed side-to-side to the right colon and brought out as a stoma. After several months, when the right colon has acquired a blood supply from the small bowel, the ileo-colon is disconnected from right colonic blood supply and brought down to the anus as a pull-through

# Ileal- J pouch



- **Play Video => J-Pouch** a segment of ileum folded back onto itself in the shape of a J and anastomosed to anus.

# Postop care



- **Excoriation:** If ileoanal PT is done in a patient with liquid stools the perineal rash will be very difficult to treat. Because of perianal pain the patients do not want to pass stool and performing irrigations will be very painful. This increases the likelihood of stool retention, enterocolitis and the need to reopen the ileostomy.

# Postop care

- **cyanoacrylate based barrier products** (starting day 0).
- **Proton pump inhibitors** to reduce acidity of stool (starting day 0)
- **Constipating diet** (avoid oily food, sugar, juices, raw fruits and vegetables)
- **Pectin** if more than 5 liquid stool /d (1 mo after surgery)
- **Loperamaide** if hyper motility and excoriation persist with pectin
- **Consult GI specialist for other options** – cholestyramine, Hyoscyamine, Diphenoxylate/Atropine (Lomotil)
- **Abandoned protocols**
  - Routine irrigation starting 2<sup>nd</sup> week for first 6month to dec number of bowel movements
  - Routine botox injection of internal sphincter to prevent HAEC

# Follow-up

Monitor growth curve, urine sodium, nutritional status

- 1month
- 3 month
- 1 year
- annually

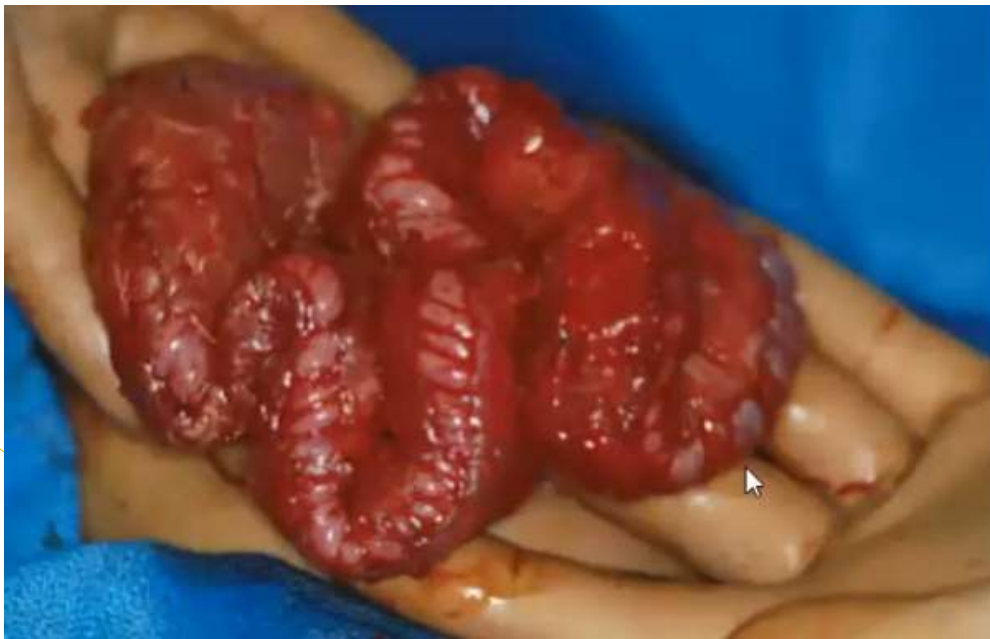## 4. Near total HD



# Initial Management

- **Stoma: frozen sections to determine site**
  - \*Some prefer more distal stoma but this has risk of chronic obstruction
- **Central venous catheter** for parenteral nutrition
- **Gastrostomy** for continuous “trophic” feeding

# Myectomy-myotomy (Zeigler)

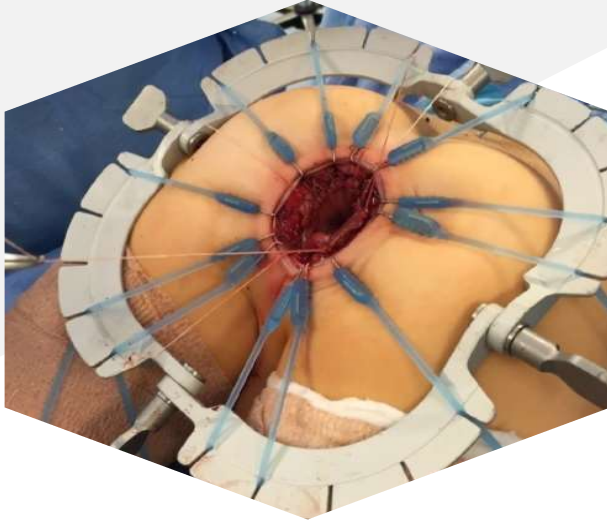


- **Historical interest only.** Myectomy of distal 40-50 cm aganglionic small bowel to allow normal peristalsis from proximal ganglionated bowel to push contents and provide more absorptive capacity. Surgery was abandoned because doesn't work well and other options have become available.

# Subsequent management

Individualized depending on length of normal bowel & clinical status

- Long term TPN
- Bowel lengthening procedures (STEP, Bianchi)
- Small bowel transplant (+ liver transplant)



# Thank You



Samuel Negash



**twitter:** @negashsamie



[negashsamie@gmail.com](mailto:negashsamie@gmail.com)



[www.linkedin.com/in/samuel-negash-743420b4](http://www.linkedin.com/in/samuel-negash-743420b4)