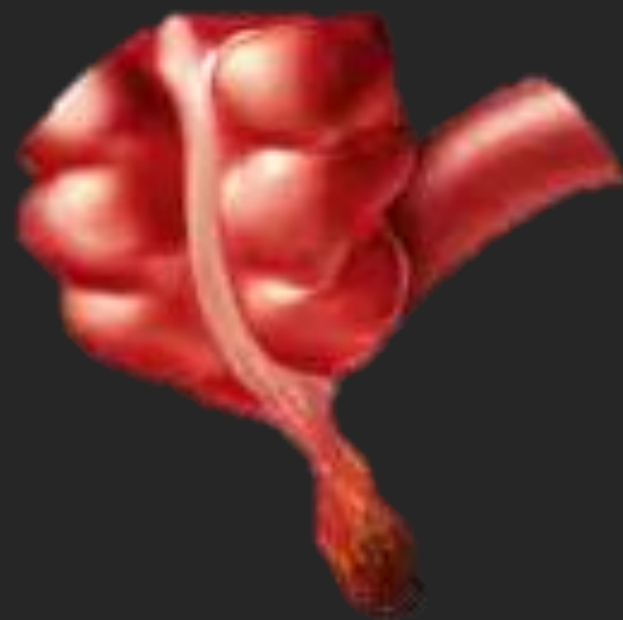



# Controversies in Pediatric Appendicitis

**Samuel Negash, M.D.**

Pediatric Surgery Resident

Addis Ababa University



## Introduction

- The **most common surgical emergency** in children (1 per 1000)
- Lifetime risk 8%, **peak in teenagers** and slightly higher in males
- **Atypical clinical features in children** is misdiagnosed as gastroenteritis
- Despite the high case volume, **numerous areas of controversy** exist



## Outline

- Basics
- Diagnosis
- Treatment
- Strategies in nonperforated
- Strategies in perforated



# Basics

---

Nomenclature

Pathophysiology

Surgical Anatomy



## Nomenclature

- Two major groups (d/t treatment and outcome)
  - uncomplicated Vs complicated
  - non-perforated Vs perforated
  - simple Vs complex
- Wide range of perforation reported (20-75%) b/c **lack of standard definition**



## Various definitions of appendicitis

- Simple = inflamed, small amount of serous/seropurulent fluid
  - \*Micro-inflammation (pathology) = normal looking appendix should be removed
- Perforated = hole ,frank pus, fecolith
- Abscess or mass = contained perforation
- **Controversial categories** (*complicated in some and uncomplicated by others*)
  - Gangrenous = ischemic, discolored wall
  - Phlegmon = suppurative/periappendocular abscess
  - Micro-perforation



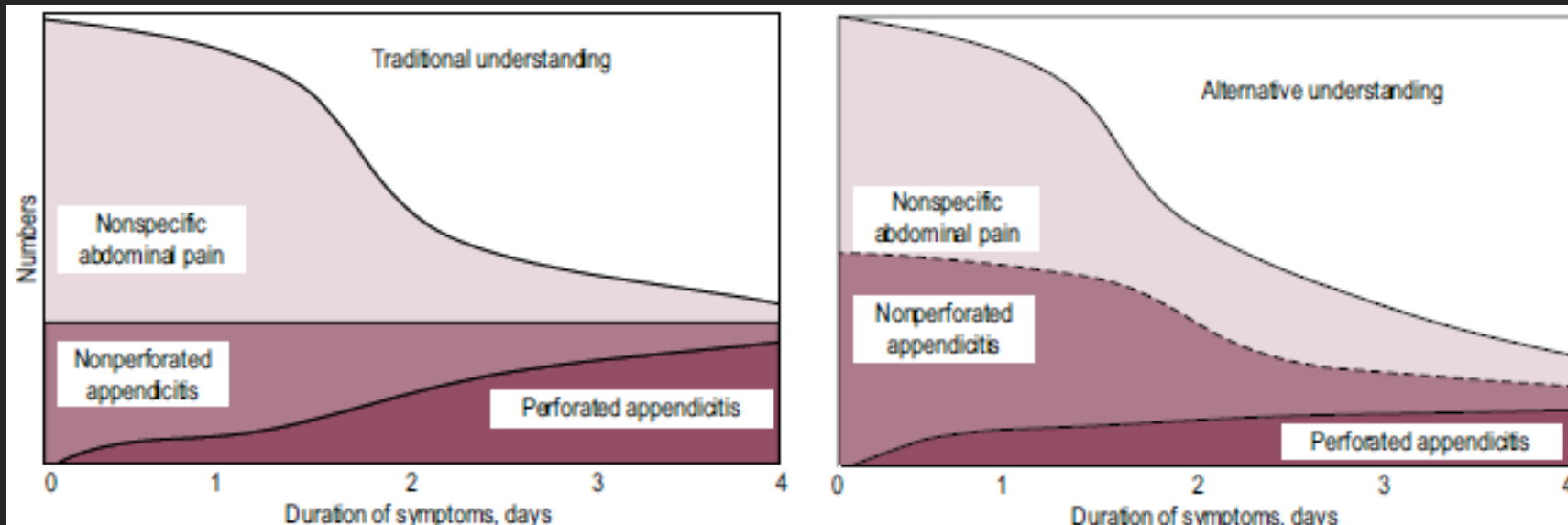
## Pathophysiology

- Appendix is a diverticulum serving as reservoir of flora and lymphoid tissue
- **Gets inflamed due to luminal obstruction** (stool, fecaliths, LN, neoplasm, torsion)
  - \*Funnel shaped during first year of life (difficult to get obstructed)
  - \*Lymphoid follicle reach maximal size during adolescence (peak age)
  - \*Fecalith less common in countries with high fiber diet
- **Luminal obstruction is present in only half...Other phenomena associated**
  - Variation with season, barometric pressure, viral infection, race, family history (3x)
- Isolated bacteria are G –ve (E. coli), less commonly G +ve (Streptococci)



## Natural history

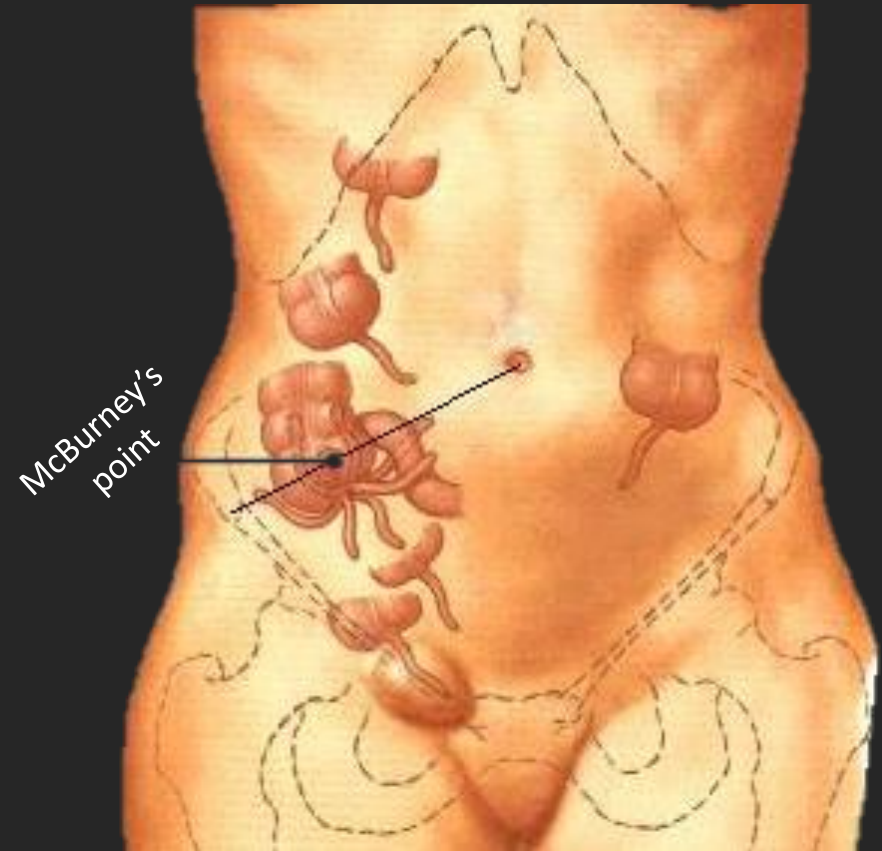
- Natural history of untreated appendicitis is not ensured (not linear)
  - Traditional understanding - Temporal progression of simple to perforated
  - Alternate understanding – simple AA can spontaneously resolve without perforation





## Surgical Anatomy

- Base is located at end of tinea of cecum but tip varies
  - Retro-cecal, sub-cecal, para-cecal
  - Pre-ileal, post-ileal
  - pelvic
- If not in RLQ, search in paravertebral, subhepatic & left
  - Malrotation
  - Wandering cecum
  - Excessively long appendix
- Artery can arise from ileocolic, ileal or cecal





# Diagnosis

---

Clinical features

Laboratory

Scoring systems

Imaging



## Clinical presentation

- Classic symptoms (50%) periumbilical pain and nausea, followed by migration of the pain to the RLQ, and subsequent vomiting & fever (low grade)
- **Atypical symptoms occurs < 5yrs** leads to missed diagnosis (80% perforated)
  - Diarrhea, dysuria, constipation, respiratory tract symptoms
  - irritability, lethargy
  - vomiting before abdominal pain
- RLQ tenderness and pain on movement (coughing or hopping)
- Rovsing sign (32%) RLQ pain on palpating LLQ is most suggestive finding



## Appendicitis in infants

- Very rare in neonates (<50 cases reported in past 30 years)
  - Neonates present with abdominal distention (confuse with NEC)
- Uncommon in <2yr
  - Vomiting is common in infants.
- Delay diagnosis b/c inability to articulate symptoms (100% perforated)



## Laboratory

- Work up includes
  - **WBC count with differentials**
  - **Urinalysis** = few WBC/RBC may be found with inflamed appendix
  - **CRP**
- Labs may be normal in early appendicitis



## Clues for Perforated appendicitis

- Clinical
  - younger age
  - longer duration of symptoms (> 3d)
  - Generally ill
  - High fever with peritonitis (high temp is uncommon in simple AA- UTI or viral)
  - Palpable mass (difficult to identify preop)
- Labs
  - Very high WBC (>16,000)
  - Elevated CRP



## Scoring systems

- more useful on evaluating children with low to intermediate likelihood of AA
  - limit the overuse of diagnostic imaging (dec cost)
  - Reduce negative appendectomy (normal appendix at surgery)
  - prevent delay in diagnosis
- Alvarado and pediatric appendicitis score (PAS) are the most widely studied
- **Debate remains on the ideal cutoff value** for both scoring systems
- Less reliable in adolescent females



	Alvarado score		Pediatric appendicitis score	
Symptoms	Migrating pain	1	“	1
	Anorexia	1	“	1
	Nausea/vomiting	1	“	1
Signs	RLQ tenderness	2	“	2
	Rebound pain	1	RLQ tenderness on Cough/hopping/ percussion	2
	Temp >37	1	Temp >38	1
Laboratory	WBC > 10,000	2	“	1
	Neutrophil > 75%	1	“	1
1-4 = low, 5-6 intermediate 7-8 probable, 9-10 = high		1-5 = low 6-10 = high		

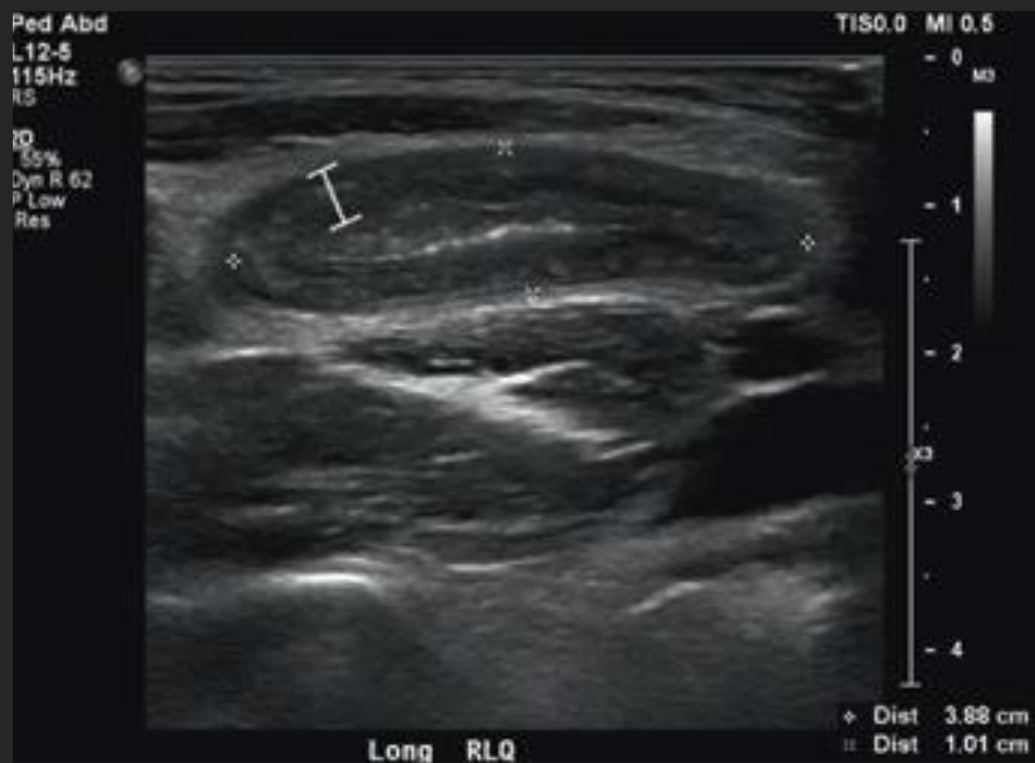

## Imaging

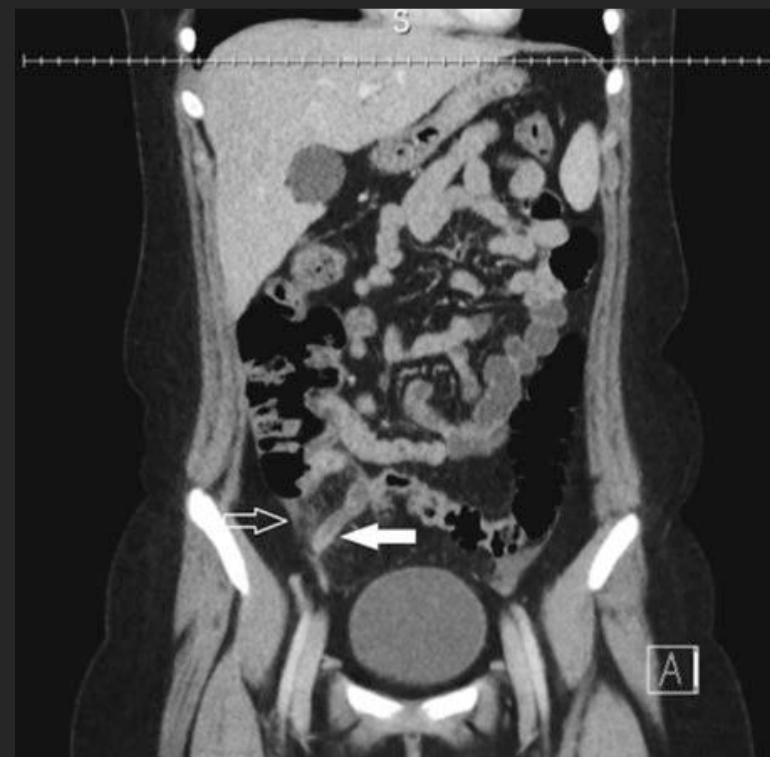- Has decreased negative appendectomy rate from 20% to 2%
- Use of ultrasound is increasing while the use of CT is decreasing
  - Maximal outer diameter >6mm (doesn't inc significantly above age 3)
  - Secondary findings = Wall thickness >3 mm, non compressibility, hyperemia, fat stranding, appendicolith, free fluid
  - Abscess = thick enhancing wall around collection
- US has high specificity but low sensitivity b/c lack of visualization of appendix
- Consider Multiple factors: availability, surgeon assessment, family preference



## Ultrasound



## CT scan





# Treatment

---

Antibiotics

Interventional radiology

Appendectomy

Complications



## Antibiotics

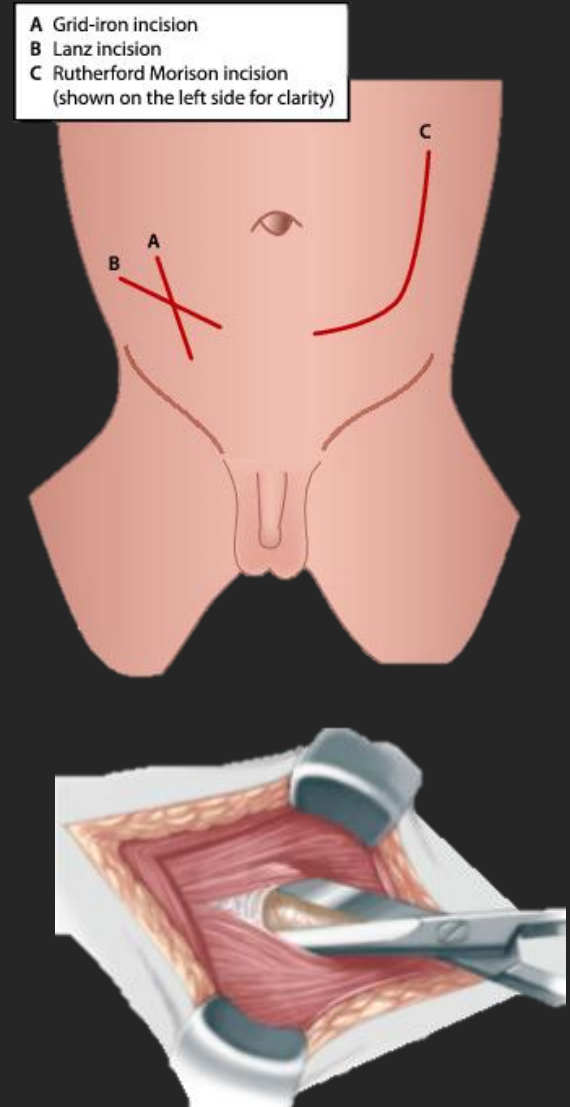
- **Immediate antibiotic, fluid and analgesia** is mandatory in all management strategies
- For the primary appendiceal infection and preventing post op complication
- **Little consensus on spectrum** (need for double pseudomonas and anerob coverage)
  - ampicillin + gentamycin + clindamycin
  - piperacillin/ tazobactam
  - cephalosporin + metronidazole
  - cephalosporin alone





## Open appendectomy

- Simple, fast, **require little material**
- Can be done under regional or local anesthesia if necessary
- Incision can be over point of tenderness or palpated mass
- Muscle splitting approach and deliver cecum through wound
- identify appendix, ligate vessel and appendix at the base
  - **\*Inversion of stump has no advantage**
- If tip not visualized, retrograde appendectomy can be done



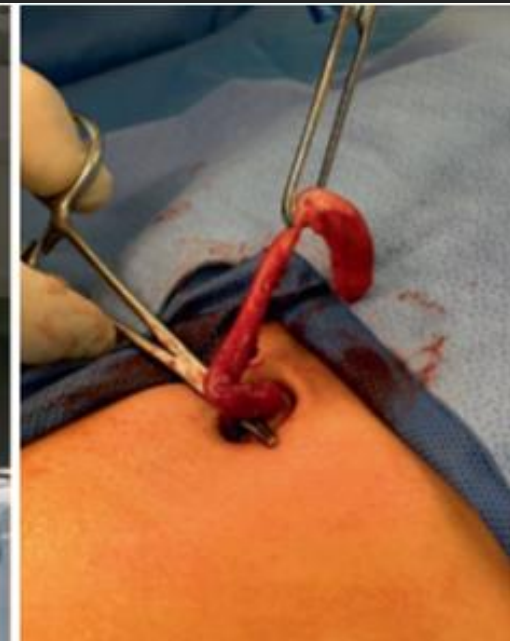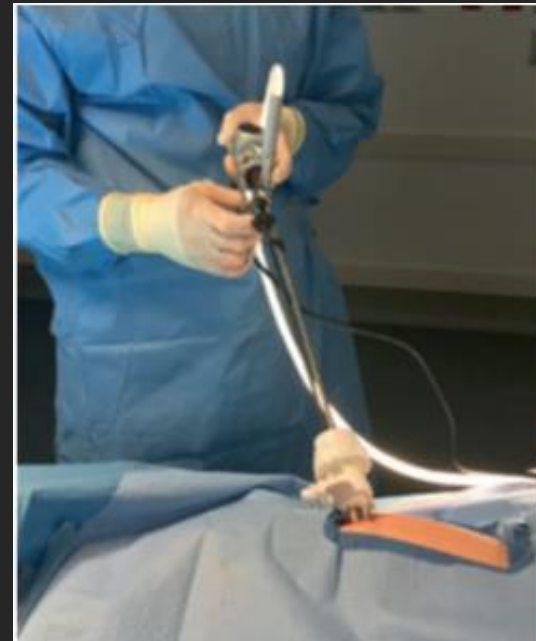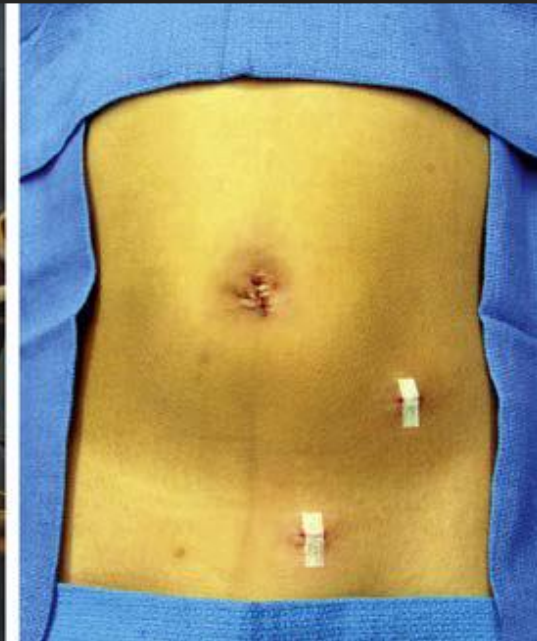
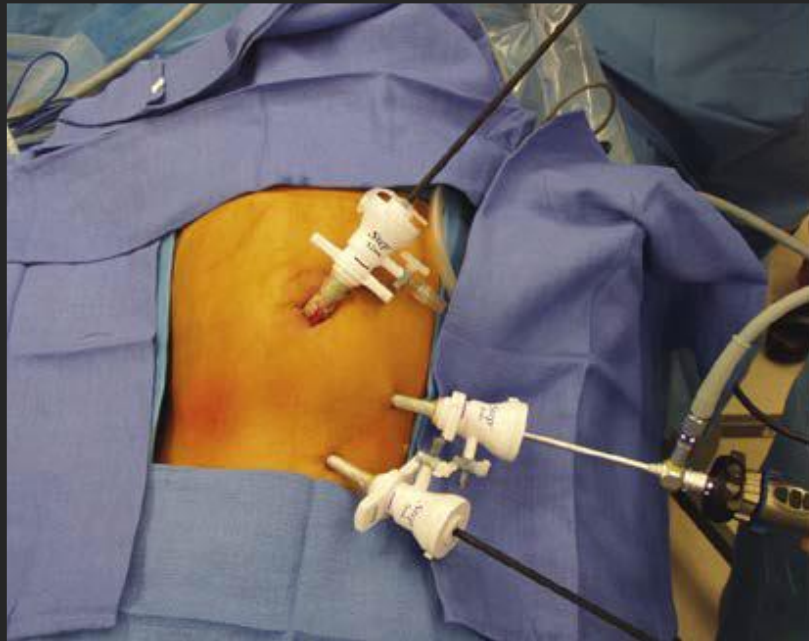


## Laparoscopic appendectomy

- Faster, **decreased SSI, SBO adhesion**, pain, scar and hospital stay but more expensive
- **Ease of confirming appendicitis** (insert only umbilical port first for exploration)
- mesoappendix can be clipped or cauterized
- Stapling and ligating (endoloop) the appendix are equally acceptable
- Modifications
  - single-incision laparoscopic surgery
  - Trans-umbilical laparoscopic-assisted appendectomy (open + single port)

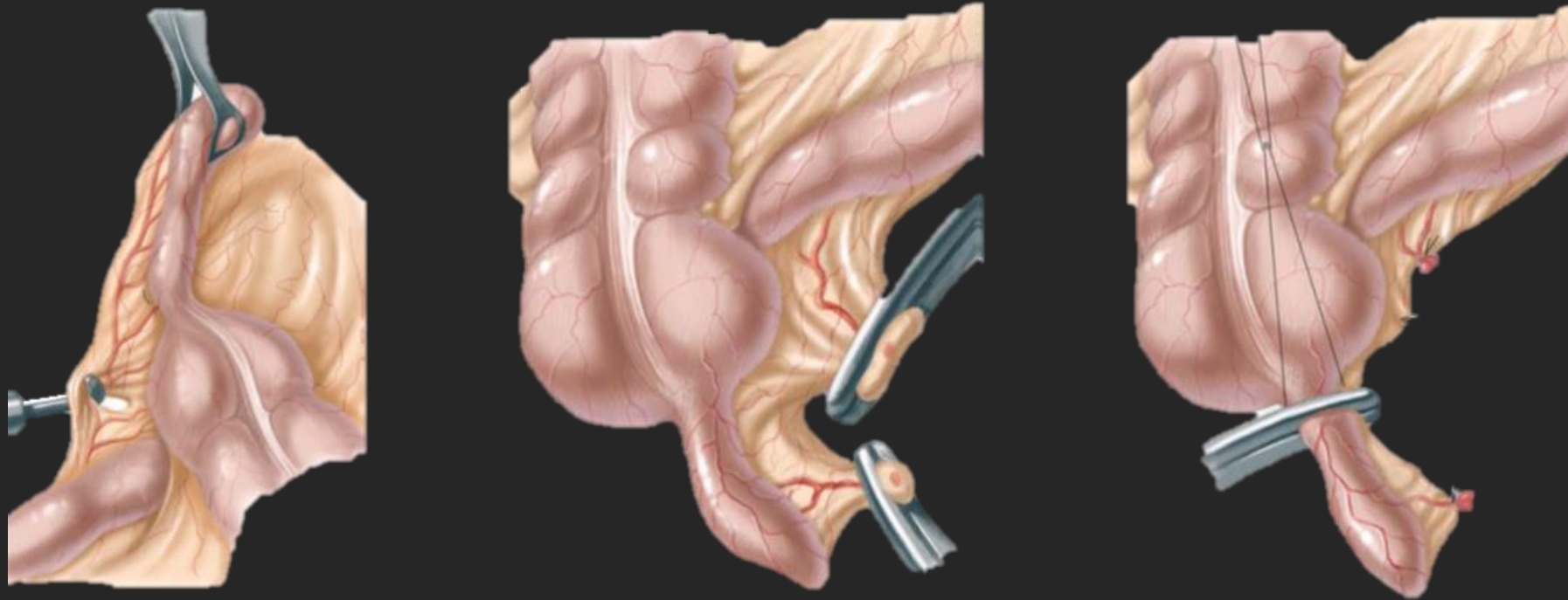


## Standard laparoscopic Vs Single port appendectomy





## Laparoscopic and Open Appendectomy technique





## Appendectomy Complications

- 10% - 15% (1% - 7% for simple, increase up to 30% in perforated)
- **Mostly infectious in nature** (superficial SSI or abdominal/pelvic abscess)
- **Adhesion** requiring intervention in 0.8%
- **Fecal fistula** (due to procedure or abscess) is <1% and >90% close spontaneously
- **Stump appendicitis** (recurrence due to incomplete removal) is rare
- **Portal or splenic vein thrombosis** (due to local sepsis) is exceedingly rare
- **Infertility in girls** (due to perforated appendicitis) is unlikely



### Intra-abdominal abscess

- <1% in simple, 20% in perforated
- No early (<48h) predictor of abscess
  - Tolerating diet on 3<sup>rd</sup> POD is a good negative predictor
- imaging before 5th POD may overestimate abscesses (fluid collection without well defined ring may resolve- residual irrigation fluid, resuscitative efforts)
- Require drainage if > 2 cm



# Strategies in Nonperforated

---

Appendectomy

Non operative management

Appendicitis in immunocompromised



## Appendectomy

- delaying appendectomy to the following morning is acceptable
  - Safety = most report no risk of perforation by 12-24hr delay and no inc complications
  - Resource utilization = inc length of stay and inc cost
  - Other consideration = stress of night time operation on family, surgeon, hospital
- Additional dose of antibiotics is not necessary post-appendectomy



### Non operative management

- Antibiotics alone is a reasonable treatment alternative to surgery in select patients
  - 1-2 days inpatient IV antibiotics until symptoms resolve followed by PO
- Challenged by misperception that delayed surgery leads to perforation
- Success rate
  - Effective in 75–80% (97% in metanalysis)
  - no increased rates of perforation
  - 14% rate of recurrent appendicitis



## Current Body of literature

Study	Year of publication	Study design	Children enrolled in non-operative management
Minnecci et al.	2016	Prospective parent preference-based trial	30
Hartwich et al.	2016	Prospective parent preference-based feasibility trial	24
Tanaka et al.	2015	Non-randomized retrospective cohort	78
Steiner et al.	2015	Non-randomized prospective cohort	45
Svensson et al.	2015	Pilot randomized control trial	24
Gorter et al.	2015	Non-randomized prospective cohort	25
Koike et al.	2014	Retrospective cohort	130
Armstrong et al.	2014	Non-randomized retrospective cohort	12
Abes et al.	2007	Retrospective cohort	16
Kaneko et al.	2004	Prospective cohort	22



## Patient selection (Predictors of failure of NOM)

- Clinical
  - Abdominal pain for >48 hours
  - signs of bowel obstruction
- Lab
  - WBC count >18,000 and/or pronounced bandemia
  - CRP >4 mg/dL
- Imaging
  - abscess or phlegmon, ? diameter >12mm
  - Appendicolith



## Appendicitis in immunocompromised

- Current evidence is inadequate to recommend a definitive management
  - **If immune deficiency is not expected to improve:-** appendectomy
  - **If immune expected to recover:-** antibiotic therapy may be considered  
(allows surgery to be delayed until modifiable issues are addressed)
  - No recommendation for NOM without surgery (under study)



# Strategies in Perforated

---

Early Appendectomy

Non operative management

Interval appendectomy



## Early appendectomy vs Non-operative management

- perforated AA without abscess
  - NOM may be attempted in patients presenting late (>5 d) without peritonitis
  - Early appendectomy is beneficial in disease beyond RLQ (diffuse peritonitis), short duration
- **Abscess** - No difference in early appendectomy vs NOM (± percutaneous drainage)
- **Mass** (well child with late presentation) are better candidate for NOM
- **\*Close monitoring is essential in NOM**: proceed to surgery if no improvement in 24-48 hr



## Antibiotics

- Duration of IV antibiotics is controversial
  - Prolonged IV = 5 days for perforated with source control, 7 days for abscess
  - Transition to PO after clinical resolution (tolerate diet, pain controlled, afebrile for 24 hr, WBC normalize) for total course (IV+PO) of 10 d
  - Further PO antibiotic not needed



## Need of Interval appendectomy

- Appendectomy 6-8 wk after successful NOM
- **May not be necessary:** Discuss with parents the risks and benefits
  - Recurrent appendicitis is low (<20%)
  - Complications of recurrent appendicitis is low
  - Complication of interval appendectomy is < 2% for simple, >2% for perforated)
  - Unlike adults, finding Incidental appendiceal carcinoid is very rare (0.2%)
- **Suggest appendectomy if there is appendicolith** b/c high recurrence (>20%)



## Intraoperative issues

- **Drain** may not be beneficial in abscess, especially if large
  - Drains should be flushed once or twice a day with saline for patency.
  - Remove catheter if <5-10 ml over 24 hr and patient has clinical improvement
- **Culture** of the fluid has no benefit in perforated appendicitis
- **Peritoneal irrigation** in perforation with peritoneal contamination
  - Irrigation with warm fluid until clear return
  - Irrigation increase postoperative development of an abscess
  - No difference of irrigation to suction alone



The End

---