

# Intussusception

---

SAMUEL NEGASH, M.D.

PEDIATRIC SURGERY RESIDENT

ADDIS ABABA UNIVERSITY



# Introduction

---

- *Latin*: intus (within) and suscipere (to receive)
- **leading cause** of intestinal obstruction in children
- Untreated, it is **potentially lethal**
- considerable **variability in outcome among**

Developed and developing countries

# Outline

---

1. Epidemiology
2. Pathology-Etiology
3. Presentation
4. Imaging
5. Treatment

# 1. Epidemiology

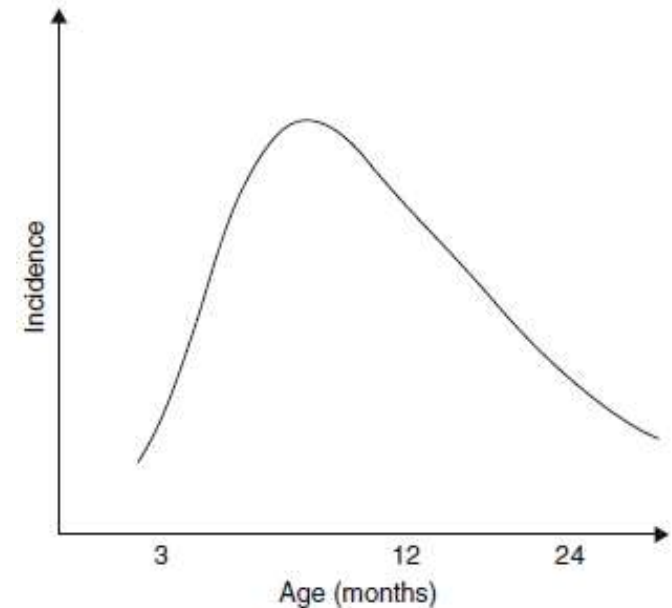
---

- *FREQUENCY OF INTUSSUSCEPTION DISPLAYS A SEASONAL VARIATION WITH MOST CASES SEEN IN MAY, JUNE, AND JULY*

# Incidence, Age, Sex

---

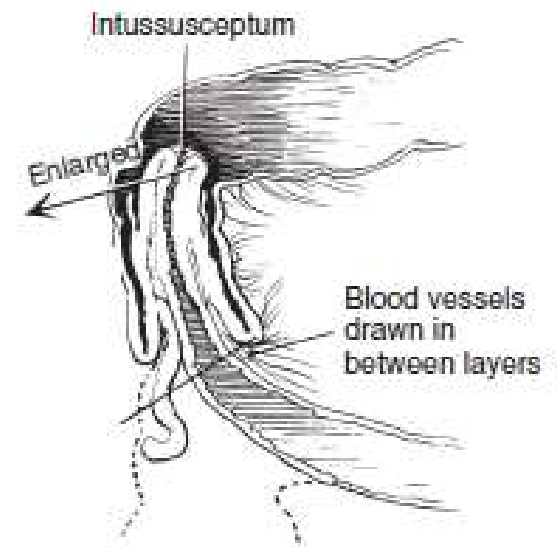
- **Incidence** 2–4 cases/1000 live births
  - \* *Seasonal variation* (viral infection in 30%)
- **Age** infant and toddlers (3 mo - 6yr)
- **Sex** M:F = 2 : 1



# Anatomic Types

---

- **85%** ileo-colic
- **10 %** ileo – ileo- colic
- 2.5% jejuno-jejunal / ileo-ileal
- 2.5% appendico- colic / ceco-colic / colo-colic



# Research from Ethiopia: Epidemiology

	Waldeyes A. 1972	Gudeta B. 1993	Anteneh G. 2016
<i>Study period</i>	8 years	10 years	4 years
<i>Sample Size</i>	42 cases	72 cases	130 cases
<i>Case per yr</i>	5	7.2	32.5
<i>Age</i>	60% < 1 yr	70% <1yr	60% < 1yr
<i>M:F</i>	2:1	1.5:1	3:1
<i>variation</i>			Peak in June
<i>Types</i>			70% Ileocolic

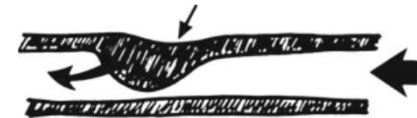## 2. Pathology-Etiology

---

*IN MOST CASES, ISCHEMIC NECROSIS NEEDS MORE THAN 72 HOURS TO DEVELOP. IF GOES UNDIAGNOSED, CAN LEAD TO DEATH WITHIN 5 DAYS.*

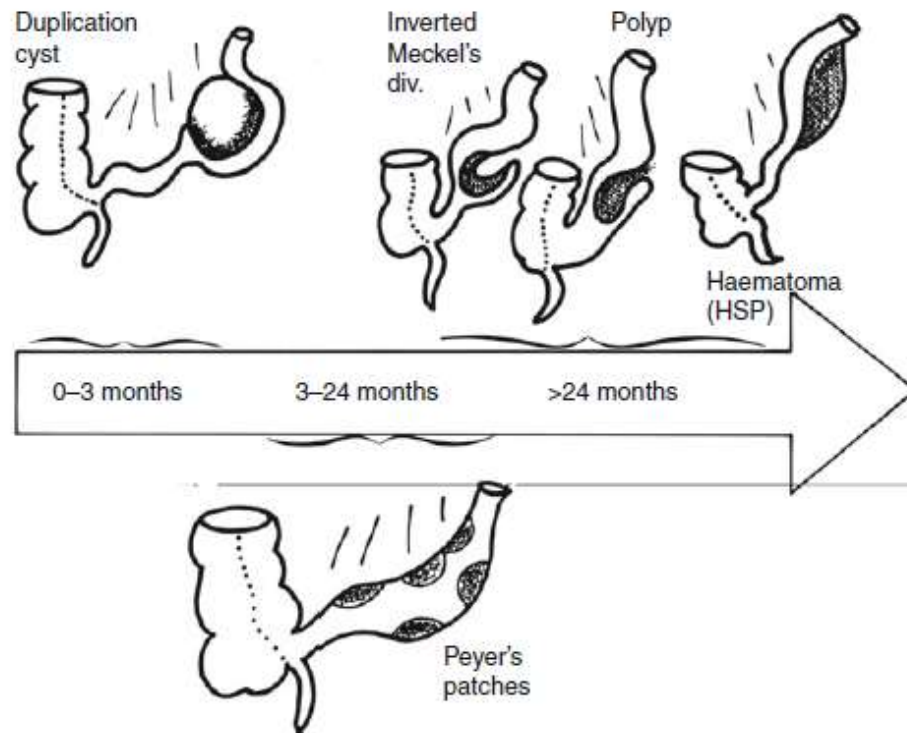
# Pathogenesis

- Proximal gut (*intussusceptum*) **invaginate/telescope** to distal segment (*intussuscepiens*) with peristalsis
- **Drags mesentery** with it (venous congestion and bowel edema) progress to arterial compromise
- **lumen is occluded** by the intussusceptum
- **20% transient** (reduced spontaneously)



Outer layer of intussusceptum devitalized first>> innermost>>intussuscepiens

# Etiology / Risk factors



- Idiopathic (95%)
- Adenovirus and rotavirus
- Dietary
- Pathologic Lead point (4%)
- post operative (1%)

# Research from Ethiopia: Etiology

---

*The NEW ENGLAND JOURNAL of MEDICINE*

ORIGINAL ARTICLE

## Evaluation of Intussusception after Monovalent Rotavirus Vaccination in Africa

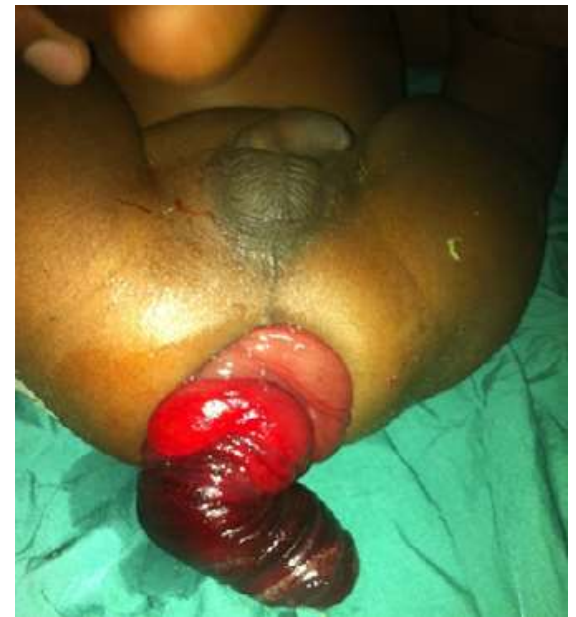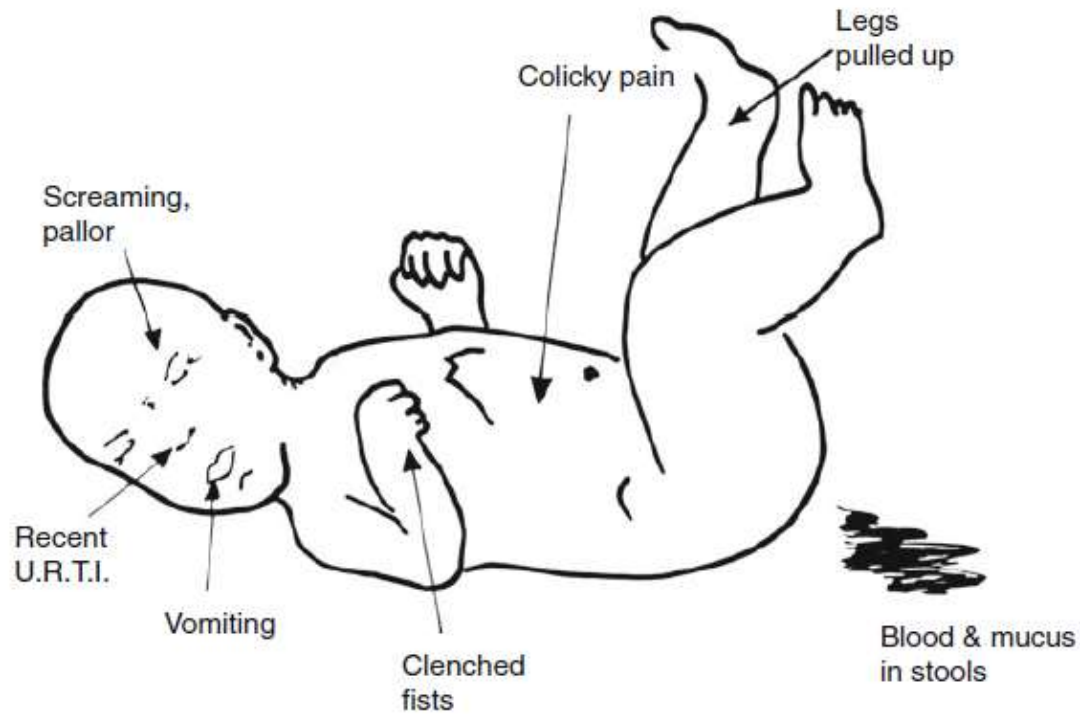
J.E. Tate, J.M. Mwenda, G. Armah, B. Jani, R. Omore, A. Ademe, H. Mujuru, E. Mpabalwani, B. Ngwira, M.M. Cortese, R. Mihigo, H. Glover-Addy, M. Mbagwa, F. Osawa, A. Tadesse, B. Mbuwayesango, J. Simwaka, N. Cunliffe, B.A. Lopman, G. Weldegebriel, D. Ansong, D. Msuya, B. Ogwel, T. Karengera, P. Manangazira, B. Bvulani, C. Yen, F.R. Zawaira, C.T. Narh, L. Mboma, P. Saula, F. Teshager, H. Getachew, R.M. Moeti, C. Eweronu-Laryea, and U.D. Parashar,

# 3. Presentation

---

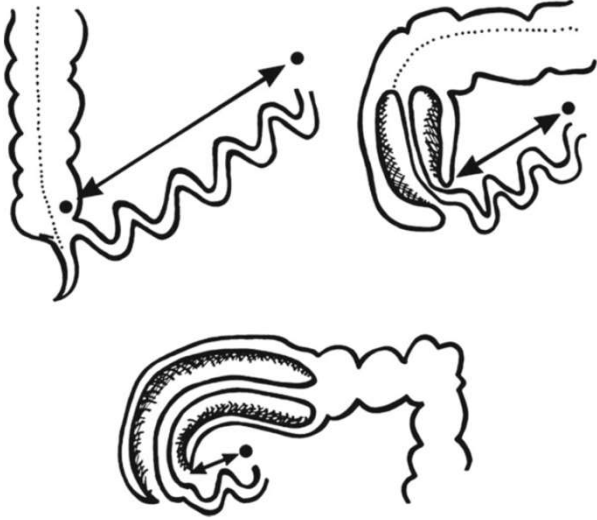
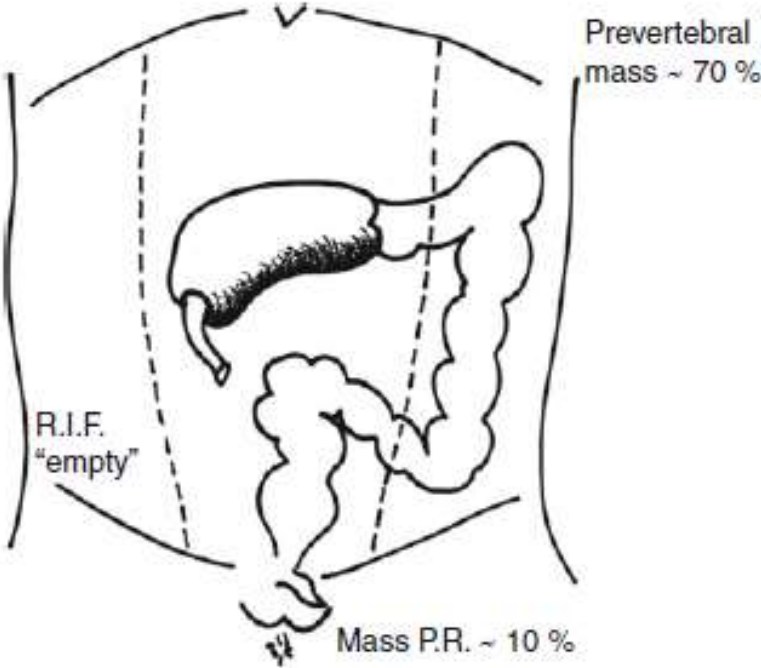
- *“THERE ARE FEW ILLNESSES IN WHICH THE CLINICAL HISTORY AND PHYSICAL FINDINGS ARE MORE SUGGESTIVE OF THE CORRECT DIAGNOSIS.” 1953 GROSS*

# History



*15% present without any obvious pain*

# Physical findings



## Research from Ethiopia: presentation

	Waldeyes A. 1972	Gudeta B. 1993	Anteneh G. 2016
<i>Study period</i>	<i>8 years</i>	<i>10 years</i>	<i>4 years</i>
<i>Sample Size</i>	<i>42 cases</i>	<i>72 cases</i>	<i>130 cases</i>
<i>duration</i>	56% >48 hrs	52% >48 hrs	73% >48 hrs
<i>Symptom combination</i>		80% = abdominal or rectal mass	2/3 <sup>rd</sup> = pain, vomiting, blood
<i>Other</i>		Uncommon in malnourished	38% had URTI

# 4. Imaging

---

- *CORRECT DIAGNOSIS OF INTUSSUSCEPTION CAN ONLY BE MADE CLINICALLY ABOUT 50% OF THE TIME. DIAGNOSTIC EVALUATION RELIES ON RADIOLOGIC IMAGING*

# Imaging

---

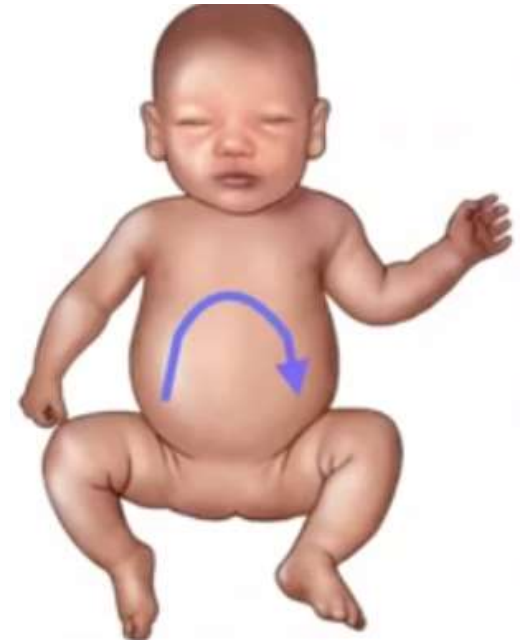	X-ray	ultrasound	Contrast enema
Accuracy	50% (controversial)	Up to 100%	Previous gold standard
Findings	<ul style="list-style-type: none"><li>- abn. gas distribution</li><li>- absent cecal gas</li><li>- right soft tissue mass</li></ul>	<ul style="list-style-type: none"><li>-doughnut, bull's eye, coiled spring</li><li>-pseudo-kidney</li></ul>	Meniscus sign
Additional	<ul style="list-style-type: none"><li>- intestinal obstruction</li></ul>	<ul style="list-style-type: none"><li>- Ischemia</li><li>- lead point</li><li>- Guide therapy</li></ul>	<ul style="list-style-type: none"><li>-Therapeutic</li></ul>

# Ultrasound technique

---

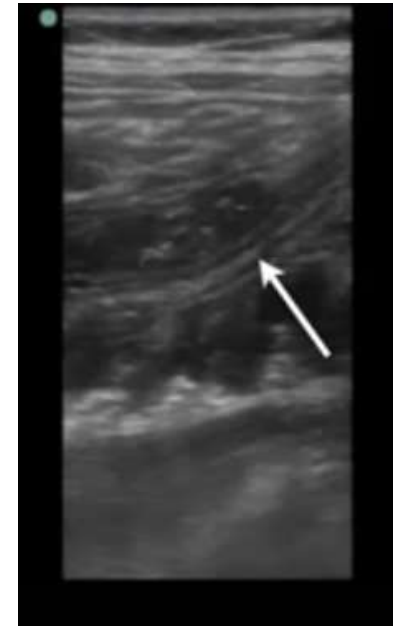
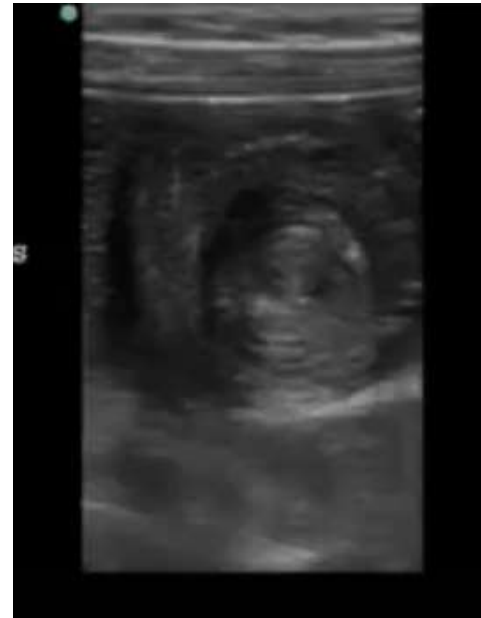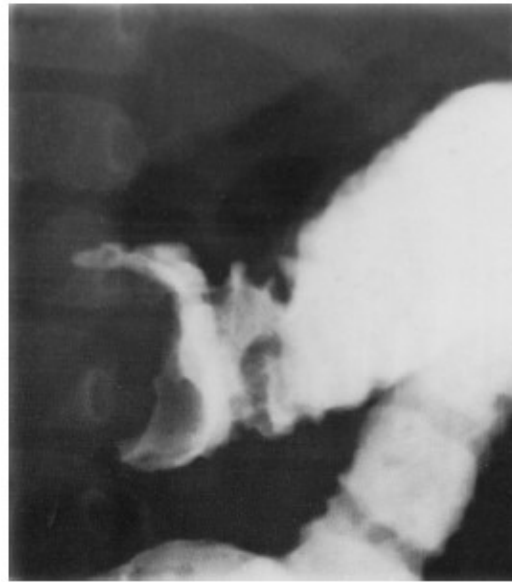
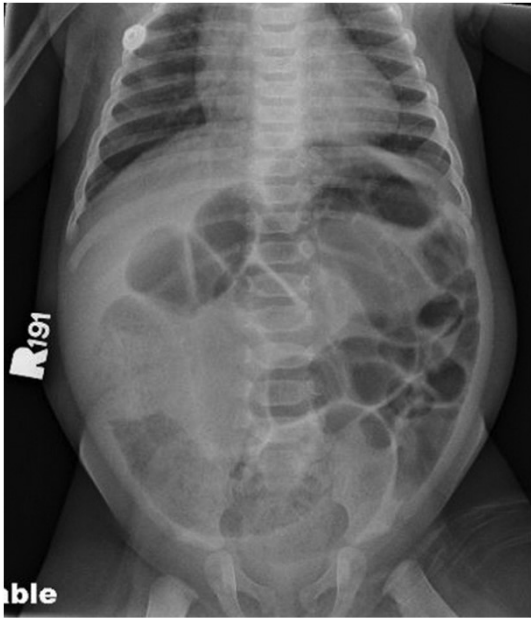


- **high frequency probe** (5-10 MHz)
- **Graded compression** (slow and steady pressure to displace overlying bowel gas)
- **Follow the colon** vs “lawn mower” technique



# Imaging

---



# 5. Treatment

---

1. INITIAL MEASURES

2. OBSERVATION

3. MEDICAL MANAGEMENT

4. RADIOLOGIC REDUCTION

5. SURGERY

6. COMPLICATIONS

## 5.1. Initial measures

---

- **Surgeon should evaluate** for signs of shock/peritonitis
- **Fluid** resuscitation (can't take dehydrated patient for hydrostatic)
- **NG tube** (if there is vomiting)
- ?Antibiotics (no compelling data to administer before hydrostatic)
- **Notify OR** that if radiologic reduction fails...directly to OR

## 5.2. Observation

---

- \*Spontaneous reduction of intussusception
  - more likely in **short** (<2.3cm, ?<3.5cm)
  - **small bowel** intussusception (86%)
  - With **gastroenteritis** (hyperactivity of inflamed bowel)
  - Incidental (**asymptomatic**) intussusception

## 5.3. Medical management (steroids)

---

- In **lymphoid hyperplasia** to prevent recurrence
  - not sufficiently studied
- Small bowel intussusception caused by **HSP**
  - If time of onset known, and experienced team follows patients

## 5.4. Radiologic reduction: Types

	Pneumatic enema	H. contrast enema	H. Saline enema
<i>Imaging</i>	<i>flouroscopy</i>	Flouroscopy	<i>ultrasound</i>
<i>Advantage</i>	<ul style="list-style-type: none"> <li>-Require lower dose</li> <li>-Easier, less messy</li> <li>-Smaller perforation</li> <li>-Less contamination</li> </ul>	<ul style="list-style-type: none"> <li>- Easier for inexperienced</li> </ul>	<ul style="list-style-type: none"> <li>- Identify lead points, bowel viability</li> <li>- Avoids radiation</li> </ul>
<i>disadvantage</i>	<ul style="list-style-type: none"> <li>-Cant use Ultrasound</li> <li>-Tension pneumopert.</li> <li>-air pass without reduction</li> </ul>	<ul style="list-style-type: none"> <li>-Messy</li> <li>-Peritoneal contamination</li> <li>- fluid shift</li> </ul>	<ul style="list-style-type: none"> <li>- needs experienced radiologist</li> </ul>

# Radiologic reduction: risk factors for failure

---

- **younger** age (<6 months)
- **longer duration** of signs and symptoms (>72 hours)
- rectal **bleeding**, radiographic signs of intestinal **obstruction**
- free peritoneal **fluid**, fluid in intussusception
- **Long** intussusceptum (?>7.3cm), in descending colon or lower
- **\*\*** *may be attempted for small bowel intussusception if long segment or symptomatic*

**Predicting the outcome is not crucial** b/c high success and low complication.

# Radiologic reduction: Procedure

---

- Insert **Foley catheter** (12-18F) and **inflate balloon** (20 ml)
- Patient Supine, with a **tight anal seal** (taping buttocks, manually pressing thighs)
- 1L NS at 35-37 degree centigrade **infused by gravity**
- **Pressure of** 120 mmHg held **for 3-5 min** (80 mmHg for young infants)
  - **\*\*1cm water = 0.74mmHg** (should be 80-160 cm above patient, can inc with experience)
- **Drain colon**
- Check 4 quadrants and pelvis for perforation

• The “**rule of threes**” (three attempts, 3 minutes’ and enema bags 3 feet above) is supported by limited evidence

# Radiologic reduction: methods to improve success rate

---

- Medications (little evidence, not routinely practiced)
  - Glucagon (to relax colonic smooth muscle no benefit in double blind study)
  - Sedation (may reduce Valsalva, therefore reducing success rates)
- Trans abdominal manipulation ?
- Delayed repeat enema
  - After 30 min up to 24 hr
  - partially successful first attempt
  - ? onset < 36 hr, T < 38, hr <150, asymptomatic

# Radiologic reduction: post-procedure


---

- Signs of successful reduction (85%)
  - disappearance of the intussusception
  - appearance of water and bubbles in the terminal ileum (sudden rush of fluid)
  - symptoms improve
- Observation after reduction: for 12-24hr, ?2hr
- Diet: short bowel rest (IV fluid) Vs as tolerated
- Antibiotics (48hr): in case of difficult reduction or fever.
- Ultrasound : any abdominal pain after reduction, or doubt success

# Radiologic reduction: Our protocol

---

## Implementing ultrasound-guided hydrostatic reduction of intussusception in a low-resource country in Sub-Saharan Africa: our initial experience in Ethiopia

Eyasu Wakjira<sup>1</sup> • Samuel Sisay<sup>1</sup> • Jonathan Zember<sup>2</sup>  • Daniel Zewdneh<sup>1</sup> • Yocabel Gorfu<sup>1</sup> • Tesfaye Kebede<sup>1</sup> • Amezene Tadesse<sup>3</sup> • Kassa Darge<sup>2</sup>



- Prolonged symptom duration (**>4 days**) and those with **ischemia** are excluded
- Enema bag **120 cm above** patient and flow with **gravity**
- Each reduction last approximately **15 min**
- Interval b/n repeat reductions is **30 min - 6hr** (average 90 min)
- Observation after procedure for **24 hrs. Repeat ultrasound only if symptomatic**

## 5.5. Surgery: Indications

---

- Peritonitis / perforation
- Pathologic lead point
- Failed non operative

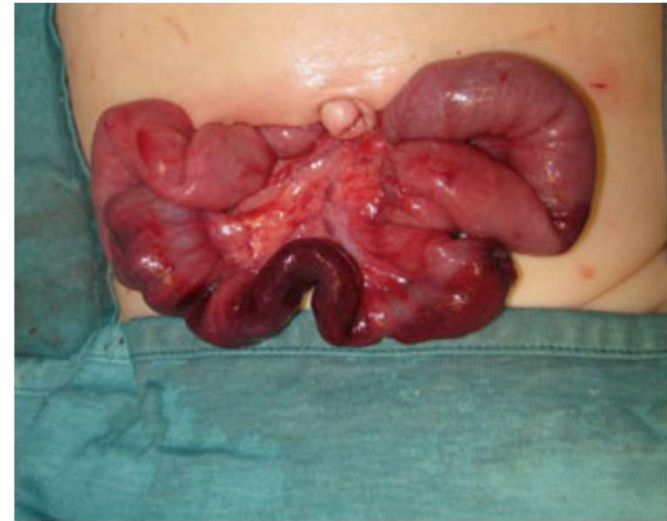
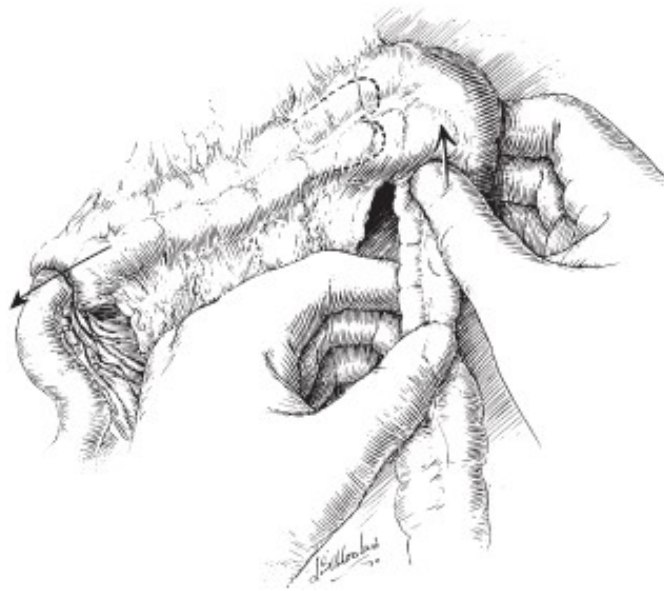
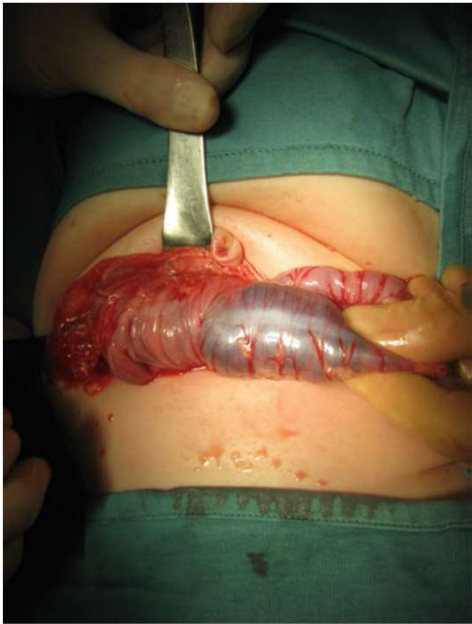
# Surgery: Laparotomy

---

- Small transverse **right-sided incision** (above or below umbilicus)
- mass palpated and is **brought outside** the wound
- **squeeze** intusceptum out of intussusciens (milk, don't pull)
- edematous, but improves with **application of warm saline** (10 min)
- **Limited bowel resection** (if not viable, irreducible with serosal tears)
- Manually **exclude pathologic lead point**
- Some perform routine appendectomy

# Surgery: Laparotomy

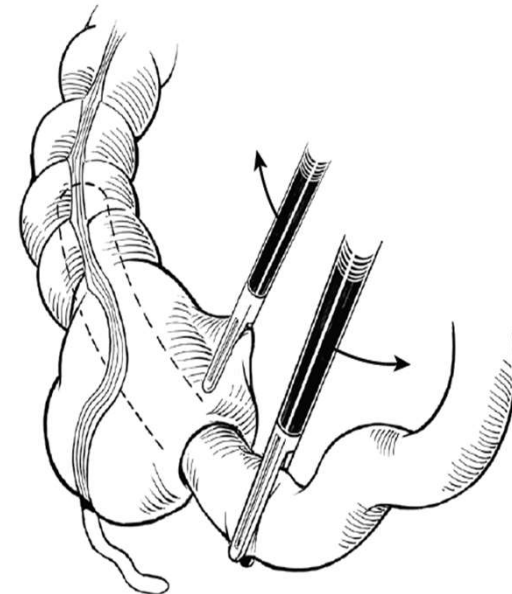
---



# Surgery: Laparoscopy

---

- Role still questioned
- reduced scarring, adhesions, pain, and hospital stay
- In contrast to laparotomy, traction usually applied proximal to the intussusciens



# Surgery: Role of appendectomy



Contents lists available at ScienceDirect

Journal of Pediatric Surgery

journal homepage: [www.elsevier.com/locate/jped surg](http://www.elsevier.com/locate/jped surg)



## Operative treatment for intussusception: Should an incidental appendectomy be performed?

Andrew Wang <sup>a</sup>, James M Prieto <sup>a</sup>, Erin Ward <sup>c</sup>, Stephen Bickler <sup>b</sup>, Marion Henry <sup>a</sup>, Karen Kling <sup>b</sup>, Hariharan Thangarajah <sup>b</sup>, Romeo Ignacio Jr. <sup>a,\*</sup>

<sup>a</sup> Department of Surgery, Naval Medical Center San Diego, San Diego, CA 92134, USA

<sup>b</sup> Division of Pediatric Surgery, Rady Children's Hospital, San Diego, CA 92123, USA

<sup>c</sup> Department of Surgery, School of Medicine, University of California, La Jolla, CA 92093, USA

Article history:

Received 15 September 2017

Received in revised form 17 October 2018

Accepted 28 October 2018

## 5.6 Complications

complications	Radiologic reduction	Surgery
rate	<1%	14% (4% for manual reduction)
Types	<i>Perforation</i>	<i>Wound infection, adhesion</i>
Mortality (developed)	<1%	<1%
- <b>Developing</b>	as high as 20%	
Recurrence	5-10%	3% (1% for manual reduction, ~0% for resection)

About 1/3<sup>rd</sup> recurrences are in 24hr, ½ in first 72 hours, majority in 6mo


## Research from Ethiopia: Treatment

	Waldeyes A. 1972	Gudeta B. 1993	Anteneh G. 2016
<i>Study period</i>	<i>8 years</i>	<i>10 years</i>	<i>4 years</i>
<i>Sample Size</i>	<i>42 cases</i>	<i>72 cases</i>	<i>130 cases</i>
<b>Bowel resection</b>			30%
<b>Morbidity</b>			34 % (Wound infection- 15%)
<b>Mortality</b>	24%	27%	4.6%

# Research from Ethiopia: Treatment

---

## Implementing ultrasound-guided hydrostatic reduction of intussusception in a low-resource country in Sub-Saharan Africa: our initial experience in Ethiopia

Eyasu Wakjira<sup>1</sup> • Samuel Sisay<sup>1</sup> • Jonathan Zember<sup>2</sup>  • Daniel Zewdneh<sup>1</sup> • Yocabel Gorfu<sup>1</sup> • Tesfaye Kebede<sup>1</sup> • Amezene Tadesse<sup>3</sup> • Kassa Darge<sup>2</sup>



- 2017, prospective study over 14 months, **47 patients**
- **87 % success** with hydrostatic reduction
- **77 % decrease** in rate of surgery
- **23% recurrence**

# WHO: Acute intussusception in infants and children a global perspective (2002)

---

- **Africa** - 17 papers from 45 countries (4 from Ethiopia)
  - Estimation **Incidence** of intussusception is not possible at present
  - male predominance in almost all papers, majority occurred in infants
  - **Seasonal variation** reported in a number of studies (actual season varies)
  - **Unusual etiology** (staple diet containing serotonin, parasitic infestations)
  - **Diarrhea** in 1/3<sup>rd</sup> , **mass on PR** (3-64%), presentation with shock
  - Treatment almost exclusively surgical, **high resection rates** (36-66%)
  - **Limited radiologic reduction** due to combination of factors (lack of 24 hr radiology service, expertise, unsuitable candidates)
  - **High mortality** (up to 54%)

*Extensive review of literature from 70 countries through medline, popline, chocrane library*

# References

- Waldeyes A. et al. *Intussusception in Ethiopia*. Ethiop Med J. 1972 10:95-103
- Gudeta B. *Intussusception in children: a ten year review*. East African Medical Journal. 1993; 70(11):730–1
- Anteneh Gadissa, et al. *Pattern and seasonal variation of intussusception in children: A retrospective analysis of cases operated in a tertiary hospital in Ethiopia*. Ethiop Med J. 2016; vol 54, No 1
- Eyasu Wakjira. *Implementing ultrasound-guided hydrostatic reduction of intussusception in a low-resource country in sub-Saharan Africa Our initial experience in Ethiopia*. Emerg Radiol. 2017
- Nianan He et al. *Risk factors associated with sonographically guided saline hydrostatic intussusception reduction in children*. J ultrasound med. 2014.; 44:1669-1675
- Andrew wang et al. *Operative treatment for intussusception: should an incidental appendectomy be performed?*. journal of pediatric surgery. 2018
- Acute intussusception in infants and children: incidence, presentation and management: a global prespective*: WHO. 2002
- Aschraft's pediatric surgery 6<sup>th</sup> edition. 2014
- Pediatric surgery (Arnold G. Coran) 7<sup>th</sup> edition. 202
- Uptodate article: intussusception in children: updated Nov 10, 2017.